ISSN print 2414-4517, ISSN online 2710-1487, https://ecm.knmu.edu.ua, ecm.journal@knmu.edu.ua

UDC: 617.721+617.723]006.81

CLINICAL AND HISTOMORPHOLOGICAL CHARACTERISTICS OF MEDIUM AND LARGE-SIZED UVEAL MELANOMA STAGES T1–3 AFTER FAILURE OF ORGAN-PRESERVING TREATMENT

Drumi D.A.[1], Polyakova S.I.[1], Artyomov O.V.[1, 2],Lytvynenko M.V.[2], Vinner N.V.[2], Chebotarova S.O.[2], Yavorsky B.I.[2], Larson L.N.[2]

[1]State Institution "The Filatov Institute of Eye Diseases and Tissue Therapy of NAMS of Ukraine", Odessa, Ukraine
[2]Odessa National Medical University, Odessa, Ukraine

Background. To assess the effectiveness of the developed combined method of Transpupillary ThermoTherapy (TTT) and Strontium-90/Yttrium-90 Brachytherapy (BT) for Uveal Melanoma (UM), it is advisable to know the features of therapeutic pathomorphosis in tumor tissue.

Aim. To evaluate the effectiveness of the Institute's treatment method for uveal melanoma based on the study of the histomorphological features of therapeutic pathomorphosis.

Materials and Methods. Fifteen enucleated eyes with continued growth of medium and large-sized UMs of stage T1–3 were studied, after the combined action of TTT and BT Sr-90/Y-90 according to the developed methodology, which was carried out at the State Institution "The Filatov Institute of Eye Diseases and Tissue Therapy of NAMS of Ukraine". The studied objects (eyeballs) were fixed in 10% neutral formalin solution, embedded in paraffin and histological sections [10–12] μm thick were made, which were stained with Harris hematoxylin and eosin and studied on a Jenamed-2 light microscope at objective magnification from 4× to 40× and eyepiece magnification of 10× followed by photoregistration with a digital video camera and assessment of therapeutic pathomorphosis. The study was conducted as part of the topic with state registration number 01224U00149.

Research Ethics. The study was conducted without human participation and did not require approval by the ethics committee.

Results. The removed melanomas were mainly mixed cell - 14 (93.3%) out of 15, one was epithelioid cell. Among mixed cell melanomas with a predominance of spindle cells, there were 3 (21.4%), epithelioid cells – 4 (28.6%). Tumors had pigmentation of varying degrees in 13 cases (86.7%), in 2 cases (13.3%) the melanoma was amelanotic. Invasion to the episclera was established in 6 cases (40.0%), the formation of an extrabulbar node – in 4 (26.7%), while the extrabulbar node was not clinically detected in 2 cases. Among the 15 melanomas studied, grade I therapeutic pathomorphosis was detected in 2, the II degree – in 3, the II–III degree – in 8 melanomas, in 2 cases there were no manifestations of pathomorphosis.

Conclusions. Therapeutic pathomorphosis after combined TTT and Sr-90/Y-90 brachytherapy was observed in 13 of 15 cases. The treatment method itself is not the primary cause of treatment failure; comparison with successfully treated cases is not feasible due to the absence of enucleation material. This study defines the limitations of the method rather than questioning its overall effectiveness.

Keywords: *ophthalmology, retina, histological examination, choroid, ionizing radiation, choroidal melanoma.*

Відповідальний автор Литвиненко М.В.
✉ 2, пров. Валіховського, м. Одеса, 65000, Україна.
E-mail: ifrehabplus@gmail.com

Corresponding author: Lytvynenko M.V.
✉ 2, Valikhovsky lane, Odessa, 65000, Ukraine.
E-mail: ifrehabplus@gmail.com

© Друмі Д.А., Полякова С.І., Артьомов О.В., Литвиненко М.В., Віннер Н.В., Чеботарьова С.О., Яворський Б.І., Ларсон Л.М. 2025

CC BY-NC-SA

© Drumi D.A., Polyakova S.I., Artyomov O.V., Lytvynenko M.V., Vinner N.V., Chebotarova S.O., Yavorsky B.I., Larson L.N., 2025

ISSN print 2414-4517, ISSN online 2710-1487, https://ecm.knmu.edu.ua, ecm.journal@knmu.edu.ua

Цитуйте українською: Друмі ДА, Полякова СІ, Артьомов ОВ, Литвиненко МВ, Віннер НВ, Чеботарьова СО, Яворський БІ, Ларсон ЛМ. Клініко-гістоморфологічна характеристика увеальних меланом стадій T1–3 середніх та великих розмірів після невдалого органозберігаючого лікування. Експериментальна і клінічна медицина. 2025;94(3):77-86. https://doi.org/10.35339/ekm.2025.94.3.dpa

Cite in English: Drumi DA, Polyakova SI, Artyomov OV, Lytvynenko MV, Vinner NV, Chebotarova SO, Yavorsky BI, Larson LN. Clinical and histomorphological characteristics of medium and large-sized uveal melanoma stages T1–3 after failure of organ-preserving treatment. Experimental and Clinical Medicine. 2025;94(3):77-86. https://doi.org/10.35339/ekm.2025.94.3.dpa [in Ukrainian].

Introduction

Organ-preserving treatment of Uveal Melanoma (UM) is currently the main treatment modality for these tumors, and the choice of its method depends mainly on the size and localization of the tumor. Most ophthalmic oncologists consider radiation therapy, in particular brachytherapy (BT), as the main treatment for UM [1–3]. Transpupillary ThermoTherapy (TTT) is used as an additional method, which researchers perform before or after brachytherapy on the residual part of the tumor [4–15]. Previously, the State Institution "The Filatov Institute of Eye Diseases and Tissue Therapy of NAMS of Ukraine" (here and after referred to as the Institute) developed a TTT technique and established the characteristic features of histomorphological and electron microscopic changes that occur in the tumor after each daily TTT session [16; 17]. This made it possible to justify and recommend the use of the developed technique as monotherapy for small-sized stage T1 (tumor prominence up to 3.0 mm, tumor base length up to 12 mm) and obtain an efficiency of 92.1% [17].

Treatment of UM patients in Ukraine is carried out in the Department of Ophthalmological Oncology of the Institute also for tumors of stages T1–3 of medium and large sizes (tumor prominence from 3.1 mm to 12.0 mm, tumor base length from <3.0 mm to 18.0 mm) in the form of a combination of TTT action and BT with strontium-90/yttrium-90 (Sr-90/Y-90) according to the developed methodology [18].

The **aim** of this study was to evaluate the effectiveness of the Institute's treatment method for uveal melanoma by examining the histomorphological features of therapeutic pathomorphism.

Materials and Methods

The material for studying the histomorphological features of therapeutic pathomorphosis was cases of uveal melanoma stages T1–3 after unsuccessful treatment with a combination of TTT and strontium-90/yttrium-90 BT, which makes it possible to clarify the mechanisms of treatment ineffectiveness and assess the limits of the method's effectiveness. The study was conducted on 15 enucleated eyes in patients with UM stages T1–3 of medium and large size (tumor prominence from 3.1 mm to 12.0 mm, tumor base length from <3.0 mm to 18.0 mm), who underwent organ-preserving treatment at the Institute in the form of a combination of TTT and Sr-90/Y-90 BT according to the developed technique. The criteria for continued tumor growth (unsuccessful treatment) were defined as follows: an increase in tumor prominence by ≥1.0 mm or an increase in the largest basal diameter by ≥1.5 mm during a follow-up period of at least 3 months, as measured by B-scan ultrasonography compared to the initial post-treatment measurements. The appearance of an extrabulbar node or new satellite lesions was also classified as continued growth.

Enucleation of eyeballs with UM was performed due to continued tumor growth; histological examination was carried out immediately after surgery. The studied objects (eyeballs) were fixed in 10% neutral formalin solution, subjected to histological processing, embedded in paraffin and histological sections 10–12 μm thick were made, which were then stained with Harris' hematoxylin and eosin and examined using a Jenamed-2 light microscope at objective magnification from 4× to 40× and eyepiece magnification

ISSN print 2414-4517, ISSN online 2710-1487, https://ecm.knmu.edu.ua, ecm.journal@knmu.edu.ua

of 10× with subsequent photoregistration using a digital video camera.

The assessment of the presence of therapeutic pathomorphosis was carried out according to the following classification of the following degrees of its severity [19]:

Stage I – more than 50% of the tumor parenchyma is preserved;

Stage II – 20–50 % of the tumor parenchyma is preserved;

Stage III – up to 20% of the tumor parenchyma is preserved in the form of separate foci;

Stage IV – complete absence of the tumor parenchyma.

The results of the study in the article are presented in the form of a description of the material with the calculation of the percentage ratio of various indicators.

Research Ethics

The study was conducted in compliance with the basic provisions of the Council of Europe Convention on Human Rights and Biomedicine, the World Medical Association Declaration of Helsinki on ethical principles of scientific medical research involving human subjects (1964–2024) and complied with the current legislation of Ukraine. All patients gave informed consent to treatment. However, our study was conducted without the participation of people, so it did not require the consent of the ethics committee.

Results

The clinical characteristics of the 15 patients with UM who underwent enucleation after unsuccessful organ-preserving treatment with the combination of TTT and Sr-90/Y-90 BT according to the developed method are as follows. The age of the patients ranged from 46 years to 75 years, there were 4 women (26.7%) and 11 men (73.3%). According to the TNM classification system, the patients were distributed by stage as follows: stage T1 (tumor prominence from 3.1 mm to 6.0 mm, tumor diameter from <3.0 mm to 9.0 mm) – 1 patient; stage T2 (tumor prominence from 3.1 to 6.0 mm, tumor diameter from 9.1 to 15.0 mm) – 8 patients; stage T3 (tumor prominence from 6.1 mm to 12.0 mm, tumor diameter from 3.1 mm to 18.0 mm) – 6 patients. It should be noted that no patient had metastatic disease at the time of enucleation (N0M0).

By location, 11 melanomas were located directly in the choroid, of which 4 were localized in the optic disc – juxtapapillary, 4 – paracentrally, 1 – paramacularly, 6 – peripherally, including three of them spreading to the ciliary body and one to the ciliary body and iris. In all patients, UM was accompanied by secondary retinal detachment above and around the tumor.

Pigmentation of the UM, which was determined ophthalmoscopically, was of varying degrees of severity: poorly pigmented melanoma prevailed in 9 cases, non-pigmented melanoma was determined in 3 cases, unevenly pigmented – in 1 case, pigmented – in 2 cases.

Two patients received 2 courses of brachytherapy, the rest received only 1 course. 7 patients received from 1 to 3 courses of TTT, the rest received from 7 to 15 courses.

According to the histomorphological conclusion, among the removed tumors there were mainly mixed cell melanomas – 14 (93.3%) out of 15, one was epithelioid cell. Among mixed cell melanomas with a predominance of spindle cells, there were 3 (21.4%), epithelioid cell – 4 (28.6%).

Histomorphologically, the presence of tumor pigmentation of varying degrees was detected in 13 cases (86.7%), in 2 cases (13.3%) the melanoma was apigmented. Invasion of the sclera to the episclera was established in 6 cases (40%), extrascleral extension with nodule formation – in 4 (26.7%), while the extrabulbar node was not detected clinically in 2 cases.

Manifestations of grade I pathomorphosis were detected in 2, grade II in 3, and grade II–III in 8 melanomas. Among the 15 studied melanomas, only two showed no manifestations of therapeutic pathomorphosis.

Therapeutic pathomorphosis after combined treatment with TTT and Sr-90/Y-90 brachytherapy according to the developed method was manifested by the presence of areas of necrobiosis in the tumor tissue (4 cases), necrosis and necrobiosis (5 cases), necrosis on the background of sclerosis-hyalinosis (1 case), sclerosis (3 cases). Lymphoid infiltration of the tumor was detected in one case (*Fig. 1–3*).

ISSN print 2414-4517, ISSN online 2710-1487, https://ecm.knmu.edu.ua, ecm.journal@knmu.edu.ua

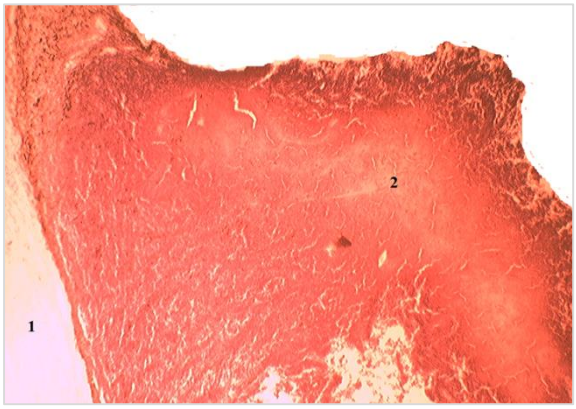

Fig. 1. Intraocular melanoma after betatherapy and TTT with a large area of necrosis-necrobiosis (2), mainly in areas of the parenchyma distant from the sclera (1). In the lower part of the photo there is a zone of sclerosis-hyalinosis. Pathomorphosis of the stage III. Hematoxylin and eosin. Magnification 100×

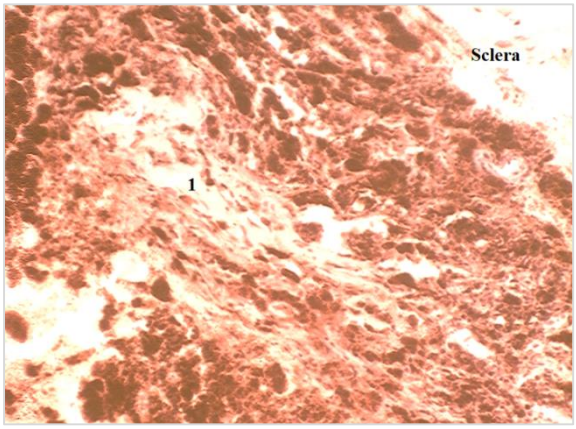

Fig. 2. Intraocular melanoma after betatherapy and TTT with large foci of hyalinized connective tissue (1) among the foci of preserved tumor parenchyma. Pathomorphosis stage II. Hematoxylin and eosin. Magnification 200×

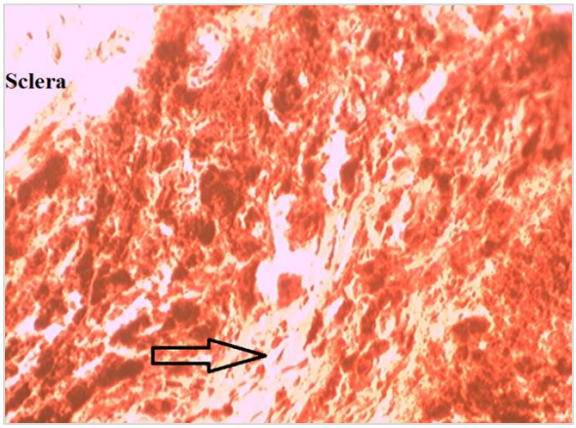

Fig. 3. Intraocular melanoma after betatherapy and TTT with small foci of sclerosis and hyalinosis (arrow) among the tumor parenchyma. Pathomorphosis stage I. Hematoxylin and eosin. Magnification 200×

It is noteworthy that the pigmentation of the tumor, which was determined by the doctor by ophthalmoscopy, sometimes does not coincide with the pigmentation of the tumor, which is detected by histomorphological examination. Thus, among three melanomas that clinically appeared to be pigmentless, according to histomorphological examination, one was unevenly pigmented, one was weakly pigmented and one was pigmented. Among 9 melanomas that were clinically determined to be weakly pigmented, according to histomorphological examination, it was found that 3 melanomas were intensely pigmented, 3 were unevenly pigmented and 2 were pigmentless. Among 2 melanomas that were clinically determined to be intensely pigmented, only one was determined to be so by histomorphological examination. The second melanoma, according to histomorphological examination, had uneven pigmentation, and conversely, the melanoma, which was clinically defined as unevenly pigmented, according to histomorphological examination was intensely pigmented.

When comparing the data of histomorphological study with clinical assessment of pigmentation, it is worth noting that the discrepancies in the assessment of the degree of pigmentation are largely related to the topography of the distribution of pigment cells in the parenchyma of the tumor node. Thus, with a relatively uniform accumulation of pigment cells at the base of the tumor node, even in the form of a narrow layer, generally occupying a small width on a histological section, the tumor can give an ophthalmoscopic picture of pigmented or intensely pigmented melanoma, although a large part of the tumor node is devoid of pigmentation. Thus, during ophthalmoscopy, the pigmentation of the tumor is formed not due to the total content of pigmented tissue, but due to the reflective pigmented layer located in the frontal plane. We observe the same dependence only due to one frontally located layer in the example of the visible color of the iris.

The minimum period between the start of organ-preserving treatment with the combined action of TTT and brachytherapy with strontium-90/yttrium-90 according to the developed

ISSN print 2414-4517, ISSN online 2710-1487, https://ecm.knmu.edu.ua, ecm.journal@knmu.edu.ua

method to enucleation of the eye was 3 months. At the same time, this was the patient with the largest tumor size – [17×15] mm, in stage T3. Of the 6 patients who received treatment and the period between the start of organ-preserving treatment with the combined action of TTT and brachytherapy with strontium-90/yttrium-90 according to the developed method was from 4 months to 12 months, the UM was in stage T3 in 4 patients and in stage T1 in 2. It should be noted that due to various circumstances, the patients did not come for a timely follow-up examination and did not receive additional treatment for the residual tumor. Thus, one patient was treated at the institute from 2014 to 2019 and a positive result was obtained locally in the form of scarring, but then she did not appear for follow-up examinations until 2024, when tumor recurrence and continued extrabulbar growth were detected, in connection with which enucleation of the eye was performed.

It should be noted that 8 patients with UM were observed for more than a year, the longest observation period was 76 months (6.3 years) – 1 patient with UM stage T1, 72 months (6 years) – 2 patients with UM stage T2, 55 months – 1 patient with UM stage T2, 46 months (3.8 years) – 1 patient with UM stage T3, 24 months (2 years) – 1 patient with UM stage T2, 22 months (1.8 years) – 1 patient with UM stage T2, 14 months (1.2 years) – 1 patient with stage T2.

The tumor size at the time of enucleation increased in 6 out of 15 patients, in one case the tumor size practically did not change, but an additional node of continued tumor growth appeared, in two patients, despite the positive local result in the form of tumor regression, extrabulbar tumor growth was detected, which was the reason for enucleation.

Discussion

According to the literature, manifestations of therapeutic pathomorphosis in UM after TTT were detected by various authors at a depth of 3.0 mm to 4.7 mm [10–15]. After brachytherapy, foci of necrosis and necrobiosis of varying degrees of severity have been described as manifestations of therapeutic pathomorphosis. We previously found that balloon-cell degeneration, dry and wet necrosis, and destructive changes in tumor vessels, which were described after TTT [16–17], are enhanced by the additional action of BT, which leads to the development of more pronounced phenomena of necrosis and necrobiosis in more pigmented tumors.

Obvious, therapeutic pathomorphosis of a tumor implies morphological changes in the tumor parenchyma, which is a set of histological and cytological patterns caused by the influence of physical, chemical (pharmacological) and biological (immunological) factors of the treatment process. These changes are expressed by characteristic histological patterns and cytological elements.

It is also important to assess the pathomorphosis by qualitative indicators, such as necrosis, hemorrhagic infiltration, edema, inflammatory infiltration (including the composition of cellular elements of the immune response), sclerosis-hyalinosis. The correlation of these qualitative manifestations of therapeutic pathomorphosis allows assessment of not only the destructive abilities, the applied therapeutic methods, but also the possible negative consequences.

Thus, the clinical consequences of therapeutic pathomorphosis are the result of two opposing processes – destruction and repair (substitution). Among the destructive changes in the parenchyma of intraocular melanomas, hemorrhagic infiltration (hemorrhagic necrosis), edema of tumor tissue, foci of necrobiosis-necrosis (coagulative necrosis) are more often detected. Apoptotic cell death, which is characteristic of chemotherapeutic effects, occurs much less frequently.

Obviously, the main goal of organ-preserving therapy is the complete removal of the tumor, which corresponds to stage 4 of pathomorphosis, the final result of which is the formation of connective tissue in place of the tumor. Unfortunately, at the time of clinical diagnosis, intraocular melanoma most often has dimensions that exceed the capabilities of modern methods of organ-preserving treatment.

However, as our experience shows, in a number of such cases, organ-preserving therapy, performed as an attempt, sometimes provides

ISSN print 2414-4517, ISSN online 2710-1487, https://ecm.knmu.edu.ua, ecm.journal@knmu.edu.ua

a relatively long-lasting stabilizing effect and can be considered as an alternative to primary enucleation. Although the outcome of such treatment is generally negative, the study of enucleated eyes allows us to obtain valuable information regarding the mechanisms of implementation of various therapeutic factors at the tissue, cellular, and ultrastructural levels.

It should be noted that assessing the therapeutic pathomorphism of intraocular melanomas remains the most challenging issue due to the lack of an objective scale for assessing regression, unlike more common tumor pathologies (such as breast cancer). Also, due to the peculiarities of organ topography, monitoring the effectiveness of treatment using a puncture biopsy is practically impossible. Therefore, enucleations of eyes with treated melanomas make it possible to gain insight of this ambiguous phenomenon in these tumors.

Recently, there has been a tendency to evaluate the therapeutic pathomorphosis taking into account immunohistochemical (changes in the proliferative activity index Ki-67) and molecular genetic (monosomy 3, BAP1) factors. Such a comprehensive pathomorphic assessment may reveal a discrepancy between the histomorphological picture, indicating grade 3 or even grade 4 pathomorphism, and the clinical consequences. This is explained by the fact that, with an unfavorable genetic profile, even single surviving clones are capable of aggressive dissemination, as is the case with BAP1 loss/monosomy 3. On the contrary, with a histomorphological picture of pathomorphosis of grade 1–2, but with a genetically favorable profile (such as EIF1AX), the clinical course may be more favorable.

The absence of immunohistochemical (Ki-67) and molecular genetic (BAP1, monosomy 3) analysis in our study is a limitation. Such assessments could have clarified why some tumors with grade II–III pathomorphosis still exhibited aggressive clinical behavior, including extrabulbar growth in 4 cases and scleral invasion in 6 cases.

Conclusions

Thus, the unsuccessful cases of organ-preserving treatment of UM with the combined action of TTT and strontium-90/yttrium-90 brachytherapy according to the developed method that we analyzed indicate that the treatment method itself is not the primary cause of treatment failure. Comparison with successfully treated cases is not feasible because successful organ-preserving treatment does not result in enucleation, and thus histomorphological material from those cases is unavailable for analysis. The present study therefore defines the limitations of the method rather than questioning its overall effectiveness. It should also be noted that in almost all cases of unsuccessful treatment of UM (14 out of 15), histomorphological signs of therapeutic pathomorphosis of grades 1–3 were detected. Histomorphological analysis of such cases provides additional insight for understanding the mechanisms and boundaries within which this method of organ-preserving treatment retains its effectiveness.

Declarations

Conflict of interest is absent.

All authors given their consent to publish the article under the terms of the Creative Commons BA-NC-SA 4.0 International License and a public agreement with the editors, to process and publish their personal data.

The authors of the manuscript state that in the process of conducting research, preparing, and editing this manuscript, they did not use any generative AI tools or services to perform any of the tasks listed in the Generative AI Delegation Taxonomy (GAIDeT, 2025). All stages of work (from the development of the research concept to the final editing) were carried out without the involvement of generative artificial intelligence, exclusively by the authors.

Funding and Acknowledgments

The study was conducted as part of a research project on the topic "To study the pathogenetic mechanisms of the clinical effect of combined treatment of medium and large-sized uveal tract melanomas and malignant neoplasms of the eyelid conjunctiva, semilunar fold and lacrimal muscle" (2022–2024), state registration number 01224U00149.

ISSN print 2414-4517, ISSN online 2710-1487, https://ecm.knmu.edu.ua, ecm.journal@knmu.edu.ua

Authors' Contributions

Contribution / Authors	A	B	C	D	E	F
Drumi D.A.			+	+		+
Polyakova S.I.	+	+				+
Artyomov O.V.				+	+	+
Lytvynenko M.V.					+	+
Vinner N.V.		+				+
Chebotarova S.O.		+				+
Yavorsky B.I.		+				+
Larson L.N.		+				+

Notes:

A – concept;
B – design;
C – data collection;
D – statistical processing and interpretation of data;
E – writing or critical editing of the article;
F – approval of the final version for publication and agreemen
to be responsible for all aspects of the work.

References

1. Fattahi S, Deufel CL, Astafurov KV, Olsen TW, Stafford SL, Neben Wittich MA, et al. Low dose iodine-125 brachytherapy and transpupillary thermal therapy for small- to medium-sized choroidal melanoma. Brachytherapy. 2026;25(2):386-95. DOI: 10.1016/j.brachy.2025.11.011. PMID: 41407569.

2. O'Day RFJ, Roelofs KA, Negretti GS, McCombe MF, Thompson K, Moncur J, Corsini L, McNab A, Howard N, Ghassemi F, Valenzuela AA. Long-term visual outcomes after ruthenium plaque brachytherapy for posterior choroidal melanoma. Eye (Lond). 2023;37(5):959-65. DOI: 10.1038/s41433-022-01944-4. PMID: 35140328.

3. Shah PN, Shanmugam M, Kagathi NM, Thaliath AT, Mohan S. Survival outcomes and prognosis predictors of uveal melanoma from Indian population. Indian J Ophthalmol. 2025;73(8):1138-45. DOI: 10.4103/IJO.IJO_350_25. PMID: 40719715.

4. Maheshwari A, Finger PT. A 12-Year Study of Slotted Palladium-103 Plaque Radiation Therapy for Choroidal Melanoma: Near, Touching, or Surrounding the Optic Nerve. Am J Ophthalmol. 2018;188:60-9. DOI: 10.1016/j.ajo.2018.01.025. PMID: 29409899.

5. Bai H, Bosch JJ, Heindl LM. Current management of uveal melanoma: A review. Clin Exp Ophthalmol. 2023;51(5):484-94. DOI: 10.1111/ceo.14214. PMID: 37076276.

6. Gallo B, Hussain R, Al-Jamal RT, Khalid H, Stoker I, Hay G, et al. Long-term visual outcomes and side effects of ruthenium-106 brachytherapy in small choroidal melanoma. Br J Ophthalmol. 2025;109(7):809-15. DOI: 10.1136/bjo-2023-324686. PMID: 39880671.

7. Murtagh P, Frentzas S, Tey A, Ribeiro C, Lubowiecki M, Lee R, et al. Tumour control, eye retention and visual acuity after radiotherapy for choroidal melanoma. BMJ Open Ophthalmol. 2026;11(1):e001944. DOI: 10.1136/bmjophth-2025-001944. PMID: 41500613.

8. Meidenbauer K, Richards Z, Yupari RJ, Bena JF, Wilkinson A, Suh J, Singh AD. Outcomes for posterior uveal melanoma: Validation of American Brachytherapy Society Guidelines. Brachytherapy. 2021;20(6):1226-34. DOI: 10.1016/j.brachy.2021.05.165. PMID: 34305017.

9. Weinberger Y, Hu J, Patel SN, Levi K, Singh AD. Uveal Melanoma: 5-Year Update on Incidence, Treatment, and Survival (SEER 1975–2020). Ocul Oncol Pathol. 2025;11(1):30-6. DOI: 10.1159/000543151. PMID: 40225965.

ISSN print 2414-4517, ISSN online 2710-1487, https://ecm.knmu.edu.ua, ecm.journal@knmu.edu.ua

10. Rao YJ, Sein J, Badiyan S, Schwarz JK, DeWees T, Grigsby P, Rao PK. Patterns of care and survival outcomes after treatment for uveal melanoma in the post-coms era (2004–2013): a surveillance, epidemiology, and end results analysis. J Contemp Brachytherapy. 2017;9(5):453-65. DOI: 10.5114/jcb.2017.70986. PMID: 29204166.

11. Kornblau I, Hopkins NS, King BA, Wiles A, Izaguirre E, Liu-Smith F, Wilson M. Characteristics and Outcomes of 237 Juxtapapillary Choroidal Melanomas Treated with Iodine-125 Plaque Brachytherapy. Ocul Oncol Pathol. 2025;11(1):46-55. DOI: 10.1159/000543521. PMID: 40225970.

12. Smidt-Nielsen I, Bagger M, Heegaard S, Andersen KK, Kiilgaard JF. Posterior uveal melanoma incidence and survival by AJCC tumour size in a 70-year nationwide cohort. Acta Ophthalmol. 2021;99(8):e1474-82. DOI: 10.1111/aos.14847. PMID: 33738986.

13. Ma ST, Hsieh YT, Wei YH, Liao SL. A 45-year experience of uveal melanoma in Taiwan: Verification of American Joint Committee on Cancer staging system and prognostic factors. J Formos Med Assoc. 2021;120(6):1361-8. DOI: 10.1016/j.jfma.2020.10.016. PMID: 33127270.

14. Gallo B, Hussain R, Al-Jamal RT, Khalid H, Stoker I, Hay G, Heimann H, Damato B. Local tumour control and patient survival after ruthenium-106 brachytherapy for small choroidal melanoma. Br J Ophthalmol. 2025;109(1):76-82. DOI: 10.1136/bjo-2023-324687. PMID: 38964829.

15. Semeniuk O, Yu E, Rivard MJ. Current and Emerging Radiotherapy Options for Uveal Melanoma. Cancers (Basel). 2024;16(5):1074. DOI: 10.3390/cancers16051074. PMID: 38473430.

16. Vit VV, Molchaniuk NI, Poliakova SI, Tsukanova IV. Ultrastructural features of choroidal melanomas after 810-nm diode-laser transpupillary thermotherapy delivered using the developed methodology. Archive of Ophthalmology of Ukraine. 2025;(6):56-62. DOI: 10.31288/oftalmolzh201965662. [In Ukrainian].

17. Vit VV, Polyakova SI, Tsukanova IV. Histomorphological changes in choroidal melanoma after transpupillary thermotherapy according to the developed method (unsuccessful cases). Archive of Ophthalmology of Ukraine. 2020;8(2):15-20. DOI: 10.22141/2309-8147.8.2.2020.209915. [In Ukrainian].

18. Pasyechnikova NV (author, owner). Certificate of Ukraine on registration of copyright for work No.135100 of 15 Apr 2025. Method of treating patients with choroidal melanoma of stages T2–T3 by combining the action of transpupillary thermotherapy according to the developed method and brachytherapy with strontium-90/yttrium-90. Kyiv: State Organization "Ukrainian National Office for Intellectual Property and Innovations". Available at: https://sis.nipo.gov.ua/uk/search/detail/1858814 [accessed 30 May 2025]. Published: Bulletin "Copyright and Related Rights" No.89 of 30 May 2025. P. 326. [In Ukrainian].

19. Avery RB, Diener-West M, Reynolds SM, Grossniklaus HE, Green WR, Albert DM. Histopathologic characteristics of choroidal melanoma in eyes enucleated after iodine 125 brachytherapy in the collaborative ocular melanoma study. Arch Ophthalmol. 2008;126(2):207-12. DOI: 10.1001/archophthalmol.2007.50. PMID:18268211.

Друмі Д.А., Полякова С.І., Артьомов О.В., Литвиненко М.В., Віннер Н.В., Чеботарьова С.О., Яворський Б.І., Ларсон Л.М.

КЛІНІКО-ГІСТОМОРФОЛОГІЧНА ХАРАКТЕРИСТИКА УВЕАЛЬНИХ МЕЛАНОМ СТАДІЙ T1–3 СЕРЕДНІХ ТА ВЕЛИКИХ РОЗМІРІВ ПІСЛЯ НЕВДАЛОГО ОРГАНОЗБЕРІГАЮЧОГО ЛІКУВАННЯ

Актуальність. Для оцінки ефективності розробленої методики комбінованої дії транспупілярної термотерапії (ТТТ) та брахітерапії (БТ) Sr-90/Y-90 на увеальну меланому (УМ) доцільно знати особливості лікувального патоморфозу в тканині пухлини.

Мета. Оцінити ефективність методу лікування увеальної меланоми, розробленого в Інституті ім. В.П. Філатова, шляхом вивчення гістоморфологічних особливостей терапевтичного патоморфозу.

ISSN print 2414-4517, ISSN online 2710-1487, https://ecm.knmu.edu.ua, ecm.journal@knmu.edu.ua

Матеріали та методи. За методикою, розробленою в ДУ «Інститут очних хвороб і тканинної терапії ім. В.П. Філатова НАМН України», досліджено 15 енуклейованих очей із продовженим ростом УМ середніх та великих розмірів стадії T1–3, після комбінованої дії ТТТ та БТ Sr-90/Y-90. Досліджувані об'єкти (очні яблука) фіксували у 10% нейтральному розчині формаліну, заливали в парафін та виготовляли гістологічні зрізи товщиною [10–12] мкм, які забарвлювали гематоксиліном та еозином Гарріса та вивчали на світловому мікроскопі Jenamed-2 при об'єктивному збільшенні від 4× до 40× та збільшенні окуляра 10× з подальшою фотореєстрацією цифровою відеокамерою та оцінкою терапевтичного патоморфозу. Дослідження проведено в межах теми з державним реєстраційним номером 01224U00149.

Етика дослідження. Дослідження було проведено без участі людей та не потребувало схвалення етичного комітету.

Результати. Видалені меланоми були переважно змішаноклітинними – 14 (93,3 %) з 15, одна була епітеліоїдноклітинною. Серед змішаноклітинних меланом з перевагою веретеноклітинних було 3 (21,4 %), епітеліоїдноклітинних – 4 (28,6 %). Пухлини мали пігментацію різного ступеня в 13 випадках (86,7 %), у 2 випадках (13,3 %) меланома була безпігментною. Інвазія до епісклери встановлена в 6 випадках (40,0 %), формування екстрабульбарного вузла – в 4 (26,7 %), при цьому екстрабульбарний вузол не був виявлений клінічно у 2 випадках. Серед 15 вивчених меланом лікувальний патоморфоз I ступеня виявлено у двох, II ступеня – у трьох, II–III ступеня – у 8 меланомах, у двох випадках не було проявів патоморфозу.

Висновки. Лікувальний патоморфоз після комбінованої дії ТТТ та брахітерапії Sr-90/Y-90 за розробленою методикою виявлено у 13 з 15 випадків. Сам метод лікування не є першопричиною неефективності; порівняння з успішними випадками неможливе через відсутність матеріалу енуклеації. Дане дослідження визначає обмеження методу, а не ставить під сумнів його загальну ефективність.

Ключові слова: *офтальмологія, сітківка, гістологічне дослідження, хоріоідея, іонізуюче випромінювання, меланома хоріоідеї.*

Received: 28 Apr 2025
Accepted: 28 Sep 2025
Published: 30 Sep 2025

Information about authors

Drumi Dmytro A. – Postgraduate Student, SI "The Filatov institute of eye diseases and tissue therapy of NAMS of Ukraine", Odessa.
Postal Address: 49/51, French bulvar, Odessa, 65061, Ukraine.
E-mail: drumi9669@gmail.com
ORCID: 0009-0004-6760-5319.

Polyakova Svetlana I. – Doctor of Medical Sciences, Senior Research Fellow, Department of Ophthalmic Oncology, SI "The Filatov institute of eye diseases and tissue therapy of NAMS of Ukraine", Odessa.
Postal Address: 49/51, French bulvar, Odessa, 65061, Ukraine.
E-mail: polyakovasvetlana1755@gmail.com
ORCID: 0009-0009-1186-8247.

ISSN print 2414-4517, ISSN online 2710-1487, https://ecm.knmu.edu.ua, ecm.journal@knmu.edu.ua

Artemov Alexander V. – Candidate of Medical Sciences, Head of the Laboratory of Pathomorphological and Electron Microscopy Research, SI "The Filatov institute of eye diseases and tissue therapy of NAMS Ukraine", Associate Professor of the Department of Histology, Cytology, Embryology and Pathological Morphology with a course in Forensic Medicine, Odessa National Medical University, Ukraine. Odessa.
Postal Address: 49/51, French bulvar, Odessa, 65061, Ukraine.
E-mail: art_onkol@ukr.net
ORCID: 0009-0004-7971-159X.

Lytvynenko Marianna V. – Candidate of Medical Sciences, Associate Professor, Associate Professor of the Department of Histology, Cytology, Embryology and Pathological Morphology with a course in Forensic Medicine, Odessa National Medical University, Ukraine.
Postal Address: 2, Valikhovsky lane, Odessa, 65000, Ukraine.
E-mail: prozector777@gmail.com
ORCID: 0000-0001-9594-3412.

Vinner Nataliia V. - Associate Professor, Candidate of Medical Sciences, Associate Professor of the Department of Human anatomy, Odessa National Medical University.
Postal Address: 2, Valikhovsky lane, Odessa, 65000, Ukraine.
E-mail: nataliia.vinner@onmedu.edu.ua
ORCID: 0000-0002-8635-6504.

Chebotarova Svitlana O. – Senior Lecturer of the Department of Human anatomy, Odessa National Medical University, Ukraine.
Postal Address: 2, Valikhovsky lane, Odessa, 65000, Ukraine.
E-mail: svetlana.chebotareva1968@gmail.com
ORCID: 0000-0002-8414-8154.

Yavorsky Boris I. – Candidate of Medical Sciences, Docent, Associate Professor of the Department of Histology, Cytology, Embryology and Pathological Morphology with a course in Forensic Medicine, Odessa National Medical University, Ukraine.
Postal Address: 2, Valikhovsky lane, Odessa, 65000, Ukraine.
E-mail: borys.yavorskyi@onmedu.edu.ua
ORCID: 0009-0003-9251-6476.

Larson Larisa N. – Assistant of Department of Histology, Cytology, Embryology and Pathological Morphology with a course in Forensic Medicine, Odessa National Medical University, Ukraine.
Postal Address: 2, Valikhovsky lane, Odessa, 65000, Ukraine.
E-mail: larysa.larson@onmedu.edu.ua
ORCID: 0009-0009-6785-5971.